

# MORPHOLOGY, DISTRIBUTION AND ROLE OF THE EPIDERMAL GLAND CELLS IN *PHORONIS PSAMMOPHILA* CORI

Catherine POURREAU\*

Station marine d'Endoume et Centre d'Océanographie, 13007 Marseille, France.

**Summary** — The epidermis of *Phoronis psammophila* Cori is composed of four gland cell types of heterogeneous distribution along the body wall. *A cells*: acidophilic, of mucopolysaccharide secretion; very numerous, particularly at the level of the start of the stomach; participate actively in the formation of the tube. *B cells*: basophilic, of sulfomucopolysaccharide secretion; numerous particularly at the base of the lophophore and near the ampulla, with a drop at the level of the start of the stomach where *A cells* predominate; actively secrete the tube. *B' cells*: basophilic in nature, of proteic secretion; less frequent; very similar by their aspect and size to the *B cells*. *C cells*: acidophilic in nature; numerous but exclusively at the base of the lophophore in *Phoronis psammophila*; lubrication for movements of the lophophore in and out of the tube is a probable role. Two zones of maximal secretion of the tube occur in *Phoronis psammophila*: at the base of the lophophore and at the anterior part of the ampulla.

**Résumé** — L'épiderme de *Phoronis psammophila* Cori comprend quatre types de cellules glandulaires de répartition hétérogène le long de la paroi du corps: *Cellules A*: acidophiles, sécrétant des mucopolysaccharides; très nombreuses surtout au niveau du départ de l'estomac; participent activement à la formation du tube. *Cellules B*: basophiles, sécrétant des sulfomucopolysaccharides; nombreuses, particulièrement à la base du lophophore et de l'ampoule, avec un net appauvrissement à la naissance de l'ampoule; ont une grande importance dans la sécrétion du tube. *Cellules B'*: basophiles, à sécrétion protéique; peu fréquentes; semblables par la taille et par l'aspect aux cellules *B*. *Cellules C*: acidophiles; uniquement présentes à la base du lophophore chez *Phoronis psammophila*; rôle probable de lubrification. Chez *Phoronis psammophila*, il existe deux régions principales de sécrétion: la base du lophophore et la partie antérieure de l'ampoule.

The body wall of *Phoronis psammophila* is composed of 6 layers which from the periphery inward are: an epidermis with a basiepithelial nervous layer; a thick basal lamina; a thin circular muscle layer; a thick longitudinal muscle layer arranged in numerous bundles; a peritoneum.

The epidermis, of variable height, consists of a unique layer of cells with a brush border with microvilli (Emig, 1971). Several types of epidermal cells have

previously been identified: coating cells, interstitial cells (Delage Herouard, 1897; Selys-Longchamps, 1907), pigment cells (Benham, 1890), gland-cells (Benham, 1890; Cori, 1890; Delage Herouard, 1897; Forneris, 1959; Harmer, 1917; Marcus, 1949; Selys-Longchamps, 1907; Silen, 1954), and diverse nervous cells (Silen, 1954).

Selys-Longchamps (1907), and Silen (1954), limit the formation of the tube to the proximal end of the ampulla, while Forneris (1959) mentions a more distal region. According to Marcus (1954), the secretion occurs throughout the length of the tube.

The purpose of this work is to describe the gland cells in the epidermis, to determine their distribution along the body wall, to define their function, and thereafter to formulate some conclusions as to the areas of formation of the tube.

## MATERIALS AND METHODS

The histological study was made on *Phoronis psammophila* collected in the Gulf of Marseille (Prado beach) during the months of September and October 1978, by means of a submarine suction sampler (Emig, 1977). After about 2 to 3 days in the sea water aquarium, the animals spontaneously left their tubes. At that time, they were harvested, fixed in Bouin for 48 hours, embedded in paraffin and cut at 5  $\mu$ m; histological techniques according to Martoja and Martoja (1967) were used on serial cross and longitudinal sections. On each transversal section, the number and size of the different epidermal secretory cells were noted, as well as the average height of the epidermis. The longitudinal sections permitted verification of the results obtained in cross-sections.

## DESCRIPTION OF THE GLAND-CELLS

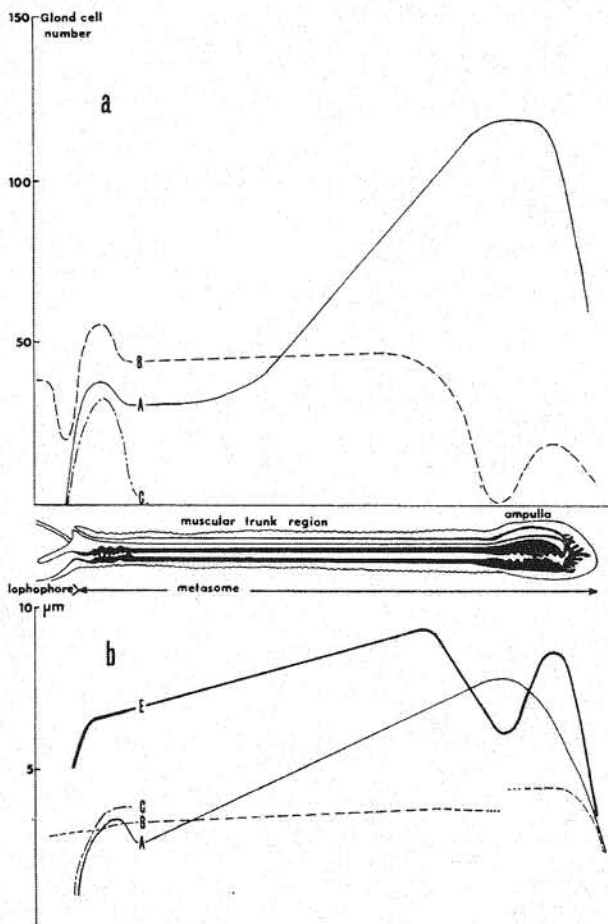
The secretory cells of the epidermis of *Phoronis psammophila* are of three types which we call: *A cells*, *B* and *B'* cells, and *C cells*. The shape of the cells varies with the height of the epidermis; from cylindrical when the epidermis is high, to flat and bulging on the surface when it is thin (Fig. 1a).

*A cells*: The size of the *A cells* varies from 1 to 7 by 2 to 4  $\mu$ m depending on the body region (Fig. 1a).

(\*) Present address: College of Wooster, Wooster, Ohio 44691, USA

Table 1. Histological response of the different epidermal gland cells and the tube in *Phoronis psammophila* (Histological techniques by Martoja and Martoja, 1967).

	STAINING				COMPOSITION OF SECRETION
	Mann-Dominici	Ramon y Caral	Alcian Blue	Periodic Acid of Schiff	
A CELL	+++ (Pink)	++ (Blue)	Negative	Negative	ACIDOPHILIC (Mucopolysaccharides)
B CELL	+++ (Bright blue)	++ (Red)	- pH : 3.5 (Bright blue) - pH : 0.5 (Bright blue)	++ (Pink)	SULFOMUCOPOLY- SACCHARIDES (acid mucopoly- saccharides)
B' CELL	++ (Green)	+ (Red)	Negative	+ (Pink)	(Hemalin-picro- indigo-carmin: yellow) GLYCOPROTEINS MUCOPROTEINS
C CELL	+ (Orange-red)	+ (Yellow)	Negative	Negative	ACIDOPHILIC NATURE
TUBE	+++ (Bright blue)	++ (Red)	- pH : 3.5 (Blue)	Negative	BASOPHILIC (acid mucopoly- saccharides) ACIDOPHILIC
	+ (Pink)	+ (Blue)			



Their nucleus, triangular in shape, is located at the base of the cells. The cytoplasmic secretory grains are conspicuous, up to  $2.5 \mu\text{m}$  in size and often seen liberated on the surface in bundles. The A cells are acidophilic (Table 1); the nature of the secretion consists of mucopolysaccharides.

— **B cells**: The size of the B cells varies from 1 to 4, by 2 to  $4 \mu\text{m}$  (Fig. 1a). The nuclei are oval and flattened at the base of the cells. The cytoplasmic secretory grains can attain  $2 \mu\text{m}$ . The response of B cells to histological staining (Table 1) defines the secretion of these cells as sulfomucopolysaccharides (acid mucopolysaccharides). The B cells are basophilic.

— **B' cells**: In regard to the majority of the basophilic cells, some have less characteristic reactions to the stains and particularly do not react to Alcian blue (Table 1). The size of the B' cells and the aspect of their nuclei are comparable to that of B cells. The cytoplasmic secretory grains are hard to distinguish. The B' cells could be a distinct gland-cell type with a secretion of proteic nature (Table 1), or a stage of evolution of

Figure 1 — a. Variation in size of the epidermis gland cells, in relation to the thickness of the epidermis along the body wall of *Phoronis psammophila*.

b. Distribution of the gland cell types along the body wall of *Phoronis psammophila*. A: A cells; B: B cells; C: C cells; E: epidermis.

the B cells, that could not be resolved in the present study.

— C Cells : The C cells, 1 to 4 by 1 to 3  $\mu\text{m}$  in size (Fig. 1a), are generally high columnar in shape often extending throughout the epidermis. Some C cells, less characteristic, are oval-shaped. The triangular basophilic nuclei are situated at the base of the cells. The cytoplasmic secretion of C cells have a birefringent aspect which masks the possible presence of secretory grains. The C cells take up little stain ; however the cytological tests indicate an acidophilic nature (Table 1). Our observations coincide with those of Selys-Longchamps (1907) and Forneris (1959) who describe these structures as congealed secretory products.

### DISTRIBUTION OF THE GLAND CELLS

Most of the secretory cells are distributed heterogeneously along the body wall of Phoronids (Fig. 1b). A comparison of the distribution curves shows a common peak for the three types of gland cells at the base of the lophophore. The C cells are localized exclusively at the base of the lophophore where they are particularly numerous, confirming the results of Selys-Longchamps (1907) for *Phoronis psammophila*. In contrast with *Phoronis hippocrepeia* where C cells have been identified in the muscular region of the ampulla by Forneris (1959), or on the tentacles by Selys-Longchamps (1907).

The B cells are the only secretory cells present on the internal surface of the tentacles (one or two cells per tentacle on a cross-section), but never on the external surface as was seen in *Phoronis hippocrepeia* (Forneris, 1959 ; Selys-Longchamps, 1907). The B cells are also present around the mouth and extending into the esophagus. After a constant distribution along the muscular body part of the animal, the abrupt decrease of the B cells at the level of the start of the stomach can be explained by a maximal concentration of the A cells which become particularly abundant in this region.

The A cells gradually increase in number along one third's of the metasome before exploding numerically to reach a maximum at the level of the start of the stomach and thereafter regress rapidly. Along the ampulla, the A cells dominate in number and also in size (Fig. 1) in relation to the other epidermal cell types.

### FUNCTION OF THE EPIDERMAL GLAND-CELLS

Liberated from the tube, the epidermis of phoronids is covered at the periphery, successively by several coating layers attaining a total thickness of about 1  $\mu\text{m}$ .

All layers are elaborated by the epidermal secretory cells.

The specific stains taken up by the tube indicate that the basophilic B cells are essentially responsible for its secretion, contrarily to the observations of Forneris (1959), Lönöy (1953), and Marcus (1949), who attribute the secretion of the tube to the acidophilic gland cells exclusively. The B cells secrete thin fibers of acid mucopolysaccharides that are layed down on the epidermis in numerous parallel layers. The total thickness of this stratified structure varies considerably (0.2 to 1  $\mu\text{m}$  in thickness) thus giving the irregular aspect of the tube. However, the acidophilic A cells participate in the elaboration of the tube. Their secretions accumulate particularly on the outer surface of the tube where they form an irregular and thin layer, generally compact in aspect. Some acidophilic grains are found scattered among the basophilic layers (Fig. 2). The tube often shows a very thin acidophilic inner layer also secreted by the A cells. The thickness of the two acidophilic peripheral layers of the tube varies little compared to that of the central basophilic one.

Around and along the body of the animal the thickness of the three layers varies greatly, thus influencing the acidophilic and/ or basophilic response of the tube to metachromatic tests : in particular, at the level of the start of the stomach the B cells are fewer in number, the A cells, very numerous and large, are more active in secreting the tube, making it more acidophilic (Fig. 2). Around the body of the animal, the central basophilic layer is often thicker on one side of the epidermis and less conspicuous on the other, giving again a more acidophilic nature to the tube.

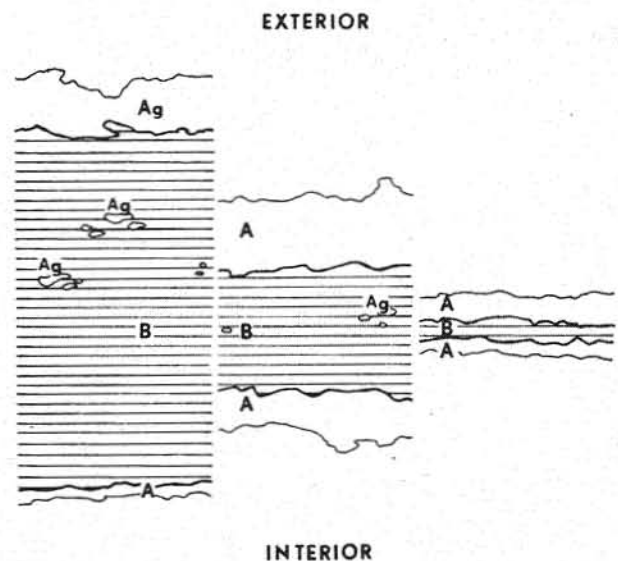


Figure 2 — Some aspects of the tube layering in relation to the thickness of the tube. — A : acidophilic coating layer ; B : basophilic coating layer ; Ag : acidophilic bundle of secretory grains.

## DISCUSSION AND CONCLUSIONS

The epidermis of *Phoronis psammophila* presents active secretion from several types of gland cells: basophilic cells, also described by previous workers such as Lönöy (1953), Marcus (1949), Selys-Longchamps (1907); acidophilic cells, mentioned by Forneris (1959), Lönöy (1957), Marcus (1949), Selys-Longchamps (1907) with a very granular secretion. In addition C cells are characterized by a congealed and birefringent secretion, the so-called "corps en masse" identified by Selys-Longchamps (1907). The former authors have described one or another of the different glandular epidermal cells which are all present in *Phoronis psammophila*.

Our histological tests on the gland cells of the epidermis, in comparison with the tube, showed that the basophilic cells are the most active in secreting the thick, stratified inner layer of the tube, while the acidophilic cells secrete the two generally much thinner outer layers (Fig. 2). These findings are in contradiction with the hypothesis of Andrews (1890), who attributes the formation of the tube to lophophoral organs, and with the prior observations made by Forneris (1959), Lönöy (1953), Marcus (1949), and Selys-Longchamps (1907) who refer exclusively to the acidophilic cells. Our results are compatible with those of Hyman (1958) who ran on the tubes of phoronids specific histological tests to determine the presence of neutral mucopolysaccharides which are in effect present in the two outer bands giving the positive reaction.

The distribution of the basophilic and acidophilic gland cells shows that the tube can be secreted throughout the length of the body, but is more active at the base of the lophophore and particularly at the level of the start of the stomach.

In the lophophore region the secretion mechanism permits the animal to repair or consolidate the upper portion of the tube which is readily exposed and easily damaged, particularly during bad weather conditions (up to 2 cm of sediment can be displaced). In the ampulla region, the active visquous secretion enhances the adherence of sand grains as the animal buries itself hindwards into the sediment forming a new tube. In the muscular region of the trunk, it allows for repair, and for the formation of a new tube.

For the C cells, exclusively located at the base of the lophophore, a lubrication role is most probable to permit the lophophoral crown to readily move in and out of the tube.

Finally, the rapid decrease of the glandular cell types at the posterior end of the ampulla can be explained by the fact that this particular area is the active contraction and expansion area for the locomotion and burrowing of the animal.

## ACKNOWLEDGMENTS

I express my gratitude to Professor J.M. Pérès, Director of the Station marine d'Endoume, who gave me the opportunity to study in his laboratory. I thank very warmly Dr. C. Donadey who is responsible for my acceptance among a high rank research team, and gave many suggestions on cytological techniques and interpretations. I am most grateful to Dr. C. Emig, whose advice, direction, and world wide authority on Phoronida, have been a substantial contribution to my work and publication.

## REFERENCES

- Andrews E.A., 1890. On a new American species of the remarkable animal *Phoronis*. *Ann. Mag. nat. Hist.*, 5 : 445-449.
- Benham W.B., 1890. The anatomy of *Phoronis australis*. *Quart. J. microsc. Sci.*, 30 : 125-158.
- Cori C.J., 1890. Untersuchungen über die Anatomie und Histologie der Gattung *Phoronis*. *Zeitschr. wiss. Zool.*, 51 : 480-568.
- Delage Y., Herouard E., 1897. Les Vermidiens, in : *Traité de Zoologie concrète*, Paris, Schleicher, 5 : 156-164.
- Emig C.C., 1971. Taxonomie et systématique des Phoronidiens. *Bull. Mus. Hist. nat.*, (Sér. 3) (Zool.) 8 : 469-568.
- , 1977. Un nouvel aspirateur sous-marin, à air comprimé. *Mar. Biol.*, 43 : 379-380.
- Forneris L., 1959. Phoronidea from Brazil. *Bol. Inst. oceanogr. S. Paulo*, 10 (2) : 1-105.
- Harmer S.F., 1917. On *Phoronis ovalis* Strethill Wright. *Quart. J. microsc. Sci.*, 62 : 115-148.
- Hyman L.H., 1958. The occurrence of chitin in the Lophophorate phyla. *Biol. Bull.*, 114 (1) : 106-112.
- Lönöy N., 1953. A comparative anatomical study on *Phoronis ovalis* Wright from Norwegian, Swedish and Brazilian waters. *Univ. Bergen Arbok*, (nat. Rekke) 2 : 1-23.
- Marcus E., 1949. *Phoronis ovalis* from Brazil. *Bol. Fac. fil. Ci. Univ. S. Paulo*, (Zool.) 14 : 157-170.
- Martoja R., Martoja M., 1967. *Initiation aux techniques de l'histoire animale*. Paris, Masson
- Selys-Longchamps M. de, 1907. *Phoronis*. *Fauna Flora Golfes Neapel*, 30 : 1-80
- Silen L., 1954. On the nervous system of *Phoronis*. *Ark. Zool.*, 6 (1) : 1-40.